



Research Article

Hepatoprotective activity of *Centella asiatica* linn. against paracetamol induced liver damage in experimental animals

V. Sivakumar, A. Mohamed Sadiq, S. Divya Bharathi

Abstract

The aim of the present study was to evaluate the hepatoprotective potential of *Centella asiatica* L. against paracetamol-induced hepatotoxicity in experimental rats. Liver toxicity was induced by paracetamol drug at a dose level of 3g/kg each, p.o for 7th and 14th days. About 50% ethanol extract of *Centella asiatica* L. (100 and 200 mg/kg) was administered orally once everyday up to 14 days. The hepatoprotective activity was assessed using different biochemical markers SGPT, SGOT, ALP, bilirubin, total protein and LDH. Meanwhile, *in vivo* antioxidant activities as SOD, CAT, GSH and, LPO were measured in liver homogenate and histological examinations were carried out to assess the hepato-protective activity. The values were subjected to one-way analysis of variance (ANOVA) followed by Tukey multiple compare test. Results were considered statistically significant at the level of $P < 0.001$. Obtained results demonstrated that the treatment with *Centella asiatica* L. (*C. asiatica*) significantly prevented the drug-induced increase in serum levels of hepatic enzymes. Furthermore, *C. asiatica* significantly reduced the lipid peroxidation in the liver tissue and restored the activities of defense antioxidant enzymes SOD, CAT and GSH towards normal. Histopathology of liver tissue showed that *C. asiatica* attenuated the hepatocellular necrosis, regeneration and repair of cells towards normal. The results of this study strongly indicate the protective effect of *C. asiatica* against paracetamol liver injury which may be attributed to its hepatoprotective activity, and there by scientifically support its traditional use.

Keywords biochemical markers, *Centella asiatica* L., hepatoprotective activity paracetamol

Introduction

Liver is the most important organ concerned with the biochemical activities in the human body. It is the major site of xenobiotic metabolism and its injury can be caused by toxic chemicals, drugs, and virus infiltration from ingestion or infection. During the detoxification, reactive oxygen species (ROS) are generated within hepatocytes that result in oxidative damage, gross cellular changes and cell death causing hepatotoxicity or liver damage. In the absence of a reliable liver protective drug in the modern system of medicine, a number of medicinal preparations in Ayurveda, the Indian system of medicine, are recommended for the treatment of liver disorders. Natural remedies from medicinal plants are considered to be effective and safe alternative treatments for hepatotoxicity [1].

The use of medicinal plants in curing diseases has being used since decades. The World Health organization (WHO) has long recognized and

Received: 24 November 2017

Accepted: 4 March 2018

Online: 12 March 2018

Authors:

V. Sivakumar ✉, A. M. Sadiq,
S. D. Bharathi
PG and Research Department of Biochemistry,
Adhiparasakthi College of Arts and Science,
Kalavai – 632506, Vellore,
Tamil Nadu, India

✉ sivakumarphdbio@gmail.com

Emer Life Sci Res (2018) 4(1): 19-26

E-ISSN: 2395-6658

P-ISSN: 2395-664X

DOI: <https://doi.org/10.31783/elrs.2018.411926>



drawn the attention of many countries to the ever increasing interest of the public in the use of medicinal plants and their products in the treatment of various ailments. India is a rich source of medicinal plants and a number of plant-derived extracts are used against diseases in various systems of medicine such as Ayurveda, Unani and Siddha [2].

Centella asiatica L. (Apiaceae) which is commonly known as Asiatic pennywort or Indian pennywort, belongs to family Apiaceae (formerly known as Umbelliferae). It is a slender, prostrate, glabrous, perennial creeping herb rooting at the nodes, with simple petiolate, palmately lobed leaves. It is extensively cultivated in Southeast Asia, India, China, Sri Lanka, etc., as vegetable or spice. *C. asiatica* has various pharmacological activities like memory enhancing, anti-inflammatory, antioxidant, wound healing, immune-stimulant, anti-anxiety (anti-hypertensive), anti-stress and anti-epilepsy. Various health benefits of *C. asiatica* have to lead to the amplified usage of this plant in food and beverages. It has been extensively used for the treatment of ailments like inflammation, syphilis, mental illness, skin diseases, rheumatism, epilepsy, hysteria, diarrhea, wounds, dehydration, and ulcers [3-4]. The present study was designed to demonstrate the hepatoprotective effects of ethanol extract of *C. asiatica* leaves against paracetamol induced liver damage in experimental animals.

Methodology

Chemicals and drugs

All the chemicals used were of analytical grade and were procured from Sigma Chemical Co., St. Louis, MO, USA, and Qualigens Fine Chemicals, Mumbai, India

Preparation of plant extract

The fresh leaves of *C. asiatica* were collected from Kakavai, Vellore, India and was authenticated by National Institute of Herbal Science, Plant Anatomy Research Center, Chennai, Tamilnadu (Voucher specimen no. PARC-2017/2034). One hundred gram of the coarsely powdered and dried material of *C. asiatica* were packed in a muslin cloth and subjected to a Soxhlet extractor for continuous hot extraction with ethanol (50%) for 72 h at 40°C. Thereafter, ethanol extract of *C. asiatica* was filtered and concentrated under reduced pressure and finally vacuum dried at temperature 40°C and the pressure 760 torr to 1 bar. The yield of the ethanol extract was 10.4% w/w.

Qualitative screening

Phytochemical screening using 1 gram of the dried ethanol extract of *C. asiatica* was done for the presence of various phyto-constituents by employing standard procedures of Kokate [5].

Animals

Healthy adult *Wistar albino* rats (150 to 200 g) were procured from Institute of Veterinary Preventive Medicine, Ranipet, India. The animals were housed separately in polypropylene cage at a temperature of 22 ± 2°C and 50 to 60% relative humidity, with a 12 h light: dark cycle respectively, for one week before and during the commencement of the experiment. Animals were allowed to access standard rodent pellet diet (Hindustan Lever Ltd., India) and drinking water. Food was withdrawn at 12 h before the experiment, though the water was allowed *ad libitum* and allocated to different experimental groups. The study protocols were approved by Institutional Animal Ethics Committee (IAEC) of Adhiparasakthi College of Arts and Science, Kalavai, Vellore, India (Reg. No. 282/ac/09/CPCSEA).

Toxicity studies

Acute toxicity study was performed for the ethanol extract of leaves of *C. asiatica* according to the Organisation for Economic Co-operation and Development guidelines (OECD)-No. 423 (2001) for acute toxic classic method [6]. Three male *Wistar albino* rats were used for each step in this study. The animals were kept fasting for overnight only on water, after which the extracts were administered intra-gastrically at



different doses of 50 and 2000 mg/kg. Food and water was further withheld for 1 h after drug administration.

Rats were closely observed for the initial 4 h after the administrations, and then once daily for 14 days to observe the animal behaviors and mortality. If mortality occurred in two out of three animals at any dose, then this dose was assigned as a toxic dose. If the mortality occurred in one animal, then this same dose was repeated to confirm the toxic dose. If mortality did not occur, the procedure was repeated for further higher dose, i.e., 2000 mg/kg. One-twentieth and one-tenth of the maximum tolerated a dose of the extract tested (2000 mg/kg) for acute toxicity, did not indicate mortality and was selected for evaluation of hepatoprotective effect of *C. asiatica* i.e., 100 and 200 mg/kg of body weight.

Paracetamol-induced hepatotoxicity

Wistar albino rats (150 to 200 g) were divided into 5 groups comprising six animals (n = 6) in each group. Group I (NC) received 1% carboxy methyl cellulose (CMC) and served as healthy control. Group II rats were administered a paracetamol (3g/kg body weight each, p.o.) for 7 and 14 days to produce hepatotoxicity [7], while group III (ethanol extract of *C. asiatica* 100) and IV (ethanol extract of *C. asiatica* 200) received orally 100 and 200 mg/kg *C. asiatica* for 14 days, prior to paracetamol drug challenge as per group II. Group V received Silymarin (standard) the known hepatoprotective compound at a dose of 100 mg/kg, p.o., daily for 14 days, and prior to paracetamol drugs challenge as per group II. All of the above drugs were prepared freshly every day and suspended in 1% CMC for administration.

The experiment was completed at the end of 14 days of the experimental period, the body weight of each rat was taken before sacrifice. The overnight fasted animals were anesthetized and sacrificed 24 h after the last dose of the drug. Blood was collected by retro-orbital plexus followed by heart puncture and allowed to clot before centrifugation at $2500 \times g$ for 15 min at 4°C to separate serum. The liver tissue was washed twice with ice-cold saline, blotted, dried, and weighed. A small section of the tissue was fixed in formalin for histological examination. The remaining tissues were stored at 20°C for not more than 12 h before analysis [8].

Assessment of hepatoprotective activity

The serum was used for estimating the biochemical parameters viz., Serum Glutamate Pyruvate Transaminase (SGPT), Serum Glutamic Oxaloacetic Transaminase (SGOT), Alkaline Phosphatase (ALP), Bilirubin (BL), Lactate dehydrogenase (LDH) and Total Protein (TP) by using standard assay kit method.

Assessment of in vivo antioxidant parameters

Hepatic tissues of rats were homogenized (10%) in phosphate buffer (pH 7.4) with a Potter-Elvehjem glass homogenizer. The homogenate was centrifuged at 12,000 rpm for 20 min at 4°C to obtain post-mitochondrial supernatant (PMS) and it was used for the estimation of lipid peroxidation (LPO) [9]. The activity of catalase (CAT), superoxide dismutase (SOD), and reduced glutathione (GSH) in the PMS of liver was measured by the methods described by Aebi [10], Kakkar et al. [11], and Upadhyay [12].

Histopathological studies

For histopathological studies, the slices of liver from each group were preserved in 10% buffered neutral formalin (pH 7.4). The tissues were mounted in the laboratory by embedding paraffin sections of 5 - 10 μ size. These sections were then stained with haematoxylin and eosin dye [13].

Statistical analysis

A result of biochemical estimations has been expressed as mean \pm Standard Error of Mean (SEM). The values were subjected to One Way Analysis of Variance (ANOVA) using Graph Prism version 3.0. The variance in a set of data has been estimated by Tukey multiple compare test. The values of $P < 0.05$ were considered statistically significant.

Results and Discussion

Qualitative screening of plant extract

The preliminary phytochemicals screening revealed that *C. asiatica* contains active pharmacological constituents such as flavonoids, alkaloids, quinones, triterpenoids, phytosterols and phenolic compounds. However, it has been already reported that such phytoconstituents like phenolic compounds, flavonoids, tannins are known to possess hepatoprotective activity in various experimental models.

Oral acute toxicity study

Rats administered with 50% ethanol extract of *C. asiatica* up to 2000 mg/kg did not show any abnormal behaviour, during initial 4 h after drug administration. No mortality was observed during 14 days after treatment. Thus, two doses (100 and 200 mg/kg.) were employed for further pharmacological studies.

Effect of Centella asiatica L. on body weight and liver weight

Body weight (initial and final) of rats treated with paracetamol decreased significantly ($P < 0.001$) when compared to control animals (Table 1). However, administration of 50% ethanol extract of *C. asiatica* in doses of 100 mg and 200 mg/kg of body weight significantly increased the weight of paracetamol treated rat ($P < 0.001$) as well as 100 mg/kg Silymarin significantly increased the body weight ($P < 0.001$) when compared to control group I.

Table 1. Effects of ethanol extract of *Centella asiatica* Linn. on body weight and liver weight levels in paracetamol induced liver toxicity in experimental animals

Groups	Animal body weight (g)		Animal liver weight (g)
	Initial	Final	
Normal control	122	128	6.52 ± 0.1
Paracetamol 3g/kg	127#	117#	8.51 ± 1.1#
Centella asiatica L. 100 mg/kg	126**	129**	6.61 ± 1.2**
Centella asiatica L. 200mg/ kg	128***	131***	6.51 ± 1.1***
Silymarin 100 mg/kg	124***	129***	6.41 ± 0.3***

Values are expressed as mean ±SD for six animals in each group

P values: * <0.05 , ** <0.01 , *** <0.001 compared with group II (Paracetamol)

P values: # <0.001 compared with respective normal control group I

Liver weights of rats treated with paracetamol were increased significantly ($P < 0.001$) from control group I. Administration of 100 and 200 mg/kg of *C. asiatica* extract significantly reduced from $P < 0.05$ to $P < 0.001$.

Effect of Centella asiatica L. ethanol extract on liver marker levels

The results of hepatoprotective effects of ethanol extract of *C. asiatica* on paracetamol intoxicated rats are shown in Table 2. Administration of paracetamol at a dose of 3 mg/kg body weight p.o. each significantly ($P < 0.001$) elevated the SGPT, SGOT, ALP, LDH and, Serum Bilirubin Level (SBL) activities, while Total Protein (TP) were significantly decreased ($P < 0.001$) when compared to control group I. Treatment of ethanol extract of *C. asiatica* at a dose of 100 and 200 mg/kg, 1 h prior to paracetamol administration significantly reversed the elevation of transaminases and ALP activities towards normal. Serum bilirubin (SBL) and LDH were significantly reduced ($P < 0.05$ to $P < 0.01$) by administration of *C. asiatica* at a dose of 100 mg/kg and 200 mg/kg as compared to hepatotoxic group II rats. The protection was better on dose 200 mg/kg and a significant increase ($P < 0.01$) was observed in the levels of TP in the serum, against the hepatotoxic control group II. Administration of silymarin significantly reversed ($P < 0.001$) the altered liver markers levels when compared to hepatotoxic group II.

Table 2. Effects of ethanol extract of *Centella asiatica* Linn. on SGPT, SGOT, ALP, SBL, LDH and TP levels in paracetamol induced liver toxicity in experimental animals

Groups	SGPT (IU/L)	SGOT (IU/L)	ALP (IU/L)	SBL (mg/dl)	LDH (IU/L)	TP (g/L)
Normal control	64.10 ± 1.10	70.18 ± 1.21	84.21 ± 1.30	23.83 ± 1.04	376.4 ± 3.10	6.71 ± 1.54
Paracetamol 3g/kg	136.21 ± 1.31#	211.03 ± 1.12#	221.03 ± 2.52#	71.17 ± 2.94#	603.1 ± 2.21#	2.81 ± 2.11#
<i>Centella asiatica</i> L. 100 mg/kg	121.32 ± 3.14**	208.11 ± 3.11**	219.62 ± 3.31**	24.17 ± 0.78**	532.2 ± 2.34**	3.82 ± 2.32**
<i>Centella asiatica</i> L. 200mg/kg	78.32 ± 1.12***	102.82 ± 1.71***	112.43 ± 1.21***	25.83 ± 1.22***	412.3 ± 2.11**	5.43 ± 1.22***
Silymarin 100 mg/kg	68.12 ± 1.02***	92.12 ± 0.21***	101.21 ± 0.32***	24.33 ± 1.13***	393.43 ± 1.24***	5.51 ± 0.11***

Values are expressed as mean ±SD for six animals in each group
P values: * <0.05 , ** <0.01 , *** <0.001 compared with group II (Paracetamol).
P values: # <0.001 compared with respective normal control group I

Effect of Centella asiatica L. ethanol extract on anti-oxidant parameters

The SOD, CAT and GSH content had significantly increased ($P < 0.05$ to $P < 0.001$) in *C. asiatica* treated groups when compare to group II whereas paracetamol drugs intoxicated group II had shown significant decrease ($P < 0.001$) in these parameters compared to control group I (Table 3). The results in Table 3. showed clear significant change in the antioxidant levels of MDA in paracetamol drugs intoxicated rats as ($P < 0.001$) compared to control group I. Treatment with *C. asiatica* at the doses of 100 and 200 mg/kg significantly prevented this elevation in the levels in LOP that were $P < 0.01$ and $P < 0.001$, respectively. In different doses, level of *C. asiatica* 200 mg/kg has shown maximum protection that was almost comparable to those of the normal control and silymarin groups.

Histopathological observations

Microscopic examination of normal liver section showed intact parenchymal cells. Mucosal glands were seen compactly arranged, consisting of cells with vesicular nuclei with nucleoli and abundant eosinophilic cytoplasm. The basement membrane was thick and intact (Figure.1a). The degeneration and necrosis of liver cells, the presence of pycnotic nuclei, granular cytoplasm and increase in intercellular spaces with inflammatory collections and loss of cellular boundaries were seen (Figure.1b). In rats group treated with *C. asiatica* extract in two different doses (Figure.1c and d), showed marked changes at the periphery, granular cytoplasm and decrease in intercellular spaces as compared to hepatotoxic control rats. Liver sections showed minimal degenerative changes of hepatocytes with minimal swelling. The treatment with extracts

Table 3. Effects of ethanol extract of *Centella asiatica* Linn. on lipid peroxides, Superoxide dismutase, Catalase and Glutathione of levels in paracetamol induced liver toxicity in experimental animals

Groups	lipid peroxides (LOP) (mmol/dl)	Superoxide dismutase (SOD) (U/mg of Protein)	Catalase (CAT) (U/mg of Protein)	Glutathione (GSH) (mg/mg of protein)
Normal control	7.20 ± 0.46	12.0 ± 1.44	32.11 ± 4.04	5.31 ± 1.62
Paracetamol 3g/kg	23.10 ± 1.21#	6.4 ± 0.24#	22.23 ± 0.24#	2.91 ± 0.21#
<i>Centella asiatica</i> L. 100 mg/kg	17.2 ± 0.23*	8.3 ± 0.24*	29.14 ± 4.24*	2.15 ± 1.26*
<i>Centella asiatica</i> L. 200mg/kg	11.6 ± 1.20***	8.1 ± 0.12***	21.35 ± 0.10***	2.42 ± 1.41***
Silymarin 100 mg/kg	12.0 ± 2.30***	9.3 ± 1.30***	30.14 ± 1.00***	3.41 ± 2.31***

Values are expressed as mean ±SD for six animals in each group
P values: * <0.05 , ** <0.01 , *** <0.001 compared with group II (Paracetamol)
P values: # <0.001 compared with respective normal control group I

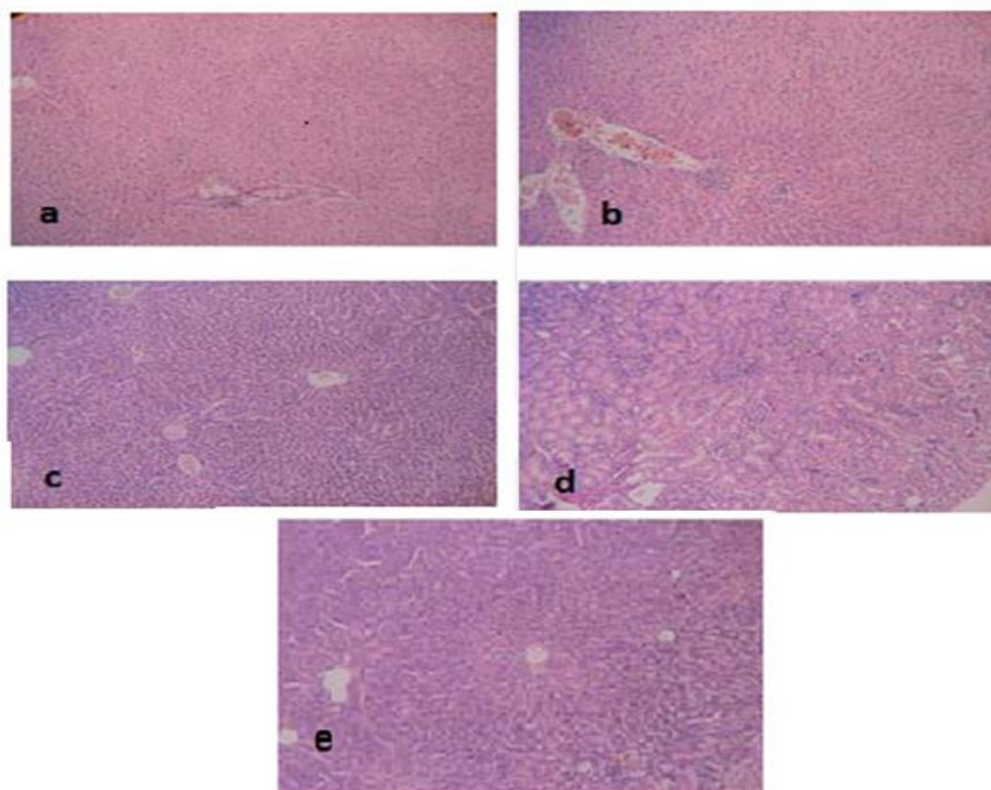


Figure 1 (a-e). Effect of ethanol extract of *Centella asiatica* L. against the Paracetamol drug induced liver toxicity in experimental animals [14]

showed that there was a significant reduction in tissue damage along with minimal evidence of inflammation. Group V treated with Silymarin 100 mg/kg, body weight as standard drug (Figure.1e) showed intact parenchymal cells. Mucosal glands were seen compactly arranged without any abnormality or any degenerative changes of hepatocytes.

Histological examination of liver tissues in rats supplemented with *C. asiatica* extract at the dose of 200 mg/kg body weight showed nearly normal tissue architecture, the absence of inflammatory cells in the central areas with significant hepatoprotective effect.

Discussion

The present findings demonstrated the hepatoprotective effect of ethanol extract of *C. asiatica* against paracetamol-induced liver toxicity in rats. A number of reports indicated that overdose of paracetamol can produce centrilobular hemorrhagic hepatic necrosis in humans and experimental animals. Modern medical science does not have, at present, a therapeutic agent that could cure the different liver disorders. In fact, the available remedies are from the traditional system of medicine [15].

The Isoniazid has got hepatotoxic potential [16]. Isoniazid metabolite hydrazine plays an important role in inducing hepatotoxicity. Isoniazid hepatotoxicity results in hepatocellular damage, thus a variety of enzymes normally located in the cytosol are released into blood stream [17]. The serum levels of a number of studied hepatic enzymes behave as diagnostic indicators for hepatic injury. The present study revealed an increased level of SGPT, SGOT, LDH and ALP in the serum of the paracetamol induced animals that certainly indicate liver damage. An increase in the levels of these marker enzymes in serum was due to the leakage of the enzymes from the liver as a result of tissue damage [18]. On concurrent treatment with methanolic extract of *C. asiatica* at a dose of 100 and 200 mg/kg respectively, the serum marker enzyme



levels were near to normal indicating the protection against liver damage (Table 2). This protective effect could be possibly due to the reduction in the tissue damage brought by the ethanol extract of *C. asiatica*. The results were compared with the standard silymarin. It is a general perception that the serum bilirubin levels are elevated in hepatic injury. A marked elevation was observed in serum bilirubin levels of paracetamol-induced rats, whereas total protein level in the serum was markedly decreased. A reduction in synthesizing proteins was seen following intoxication of the liver with hepatotoxicants. As seen in the silymarin treated group and ethanol extract of *C. asiatica*, all studied parameters were restored to the normal condition from the abnormal ones.

The body has an effective defence mechanism to prevent and neutralize the free radical induced damage. This is proficient by a set of endogenous antioxidant enzymes such as SOD, and catalase. Suppression of the anti-oxidant system in paracetamol drugs intoxicated rats has been reported earlier [19].

The significantly reduced activities of SOD and CAT pointed out the hepatic damage in the rats administered with paracetamol drugs, but on treatment with 100, and 200 mg/kg of *C. asiatica* groups showed a significant increase in the level of these enzymes due to the ability of the administered compounds to scavenge reactive oxygen species.

Increase in the level of lipid peroxides in liver reflected the hepatocellular damage. The depletion of antioxidant defenses and/or raise in free radical production deteriorates the prooxidant-antioxidant balance, leading to oxidative stress-induced cell death [20]. Depletion of reduced glutathione (GSH) is known to result in enhanced lipid peroxidation and excessive lipid peroxidation can cause increased glutathione consumption [21], as observed in the present study that indicates the antioxidant activity of the *C. asiatica*. Furthermore, on treatment with different doses of *C. asiatica* (100 and 200mg/kg) significant reduction in the level of lipid peroxidation is an important cause of destruction and damage to hepatocellular membranes, and elevation in the level of GSH in liver. The increase in hepatic GSH level in the rats treated with *C. asiatica* may be due to de novo GSH synthesis or GSH regeneration. The hepatoprotective effect of the *C. asiatica* was further assessed by the histopathological examinations that could be only possible by the overall protective character of the extract. On phytochemical screening, *C. asiatica* revealed the presence of flavonoids, steroidal, alkaloids and triterpenes as the major chemical constituents. Hence, it is possible that the mechanism of hepatoprotection of *C. asiatica* is may be due to its antioxidant property [22] present in these phytochemicals. Our finding also supports the previous hepatoprotective study carried out by *C. asiatica*. Additionally, reducing the oxidative stress imposed by paracetamol drugs as well as others like antitubercular and healing property, which may prevent hepatic damage. This study involved the determination of hepatoprotective activity of the *C. asiatica* extract against hepatotoxicity induced by paracetamol drugs. Further investigations are required for the identification of active constituents responsible for the hepatoprotection.

Conclusion

The ethanol extract of *C. asiatica* has shown dose-dependent activity against paracetamol-induced hepatic damage in experimental rats. The hepatoprotective effect of the *C. asiatica* was further corroborated by the histopathological examinations. Further investigation of these promising protective effects of *C. asiatica* against paracetamol drug-induced hepatic injury may have a considerable impact on developing clinically feasible strategies to treat patients with hepatotoxicity.

Acknowledgements

The author(s) would like to acknowledge Honorable Principal, Dr. A. Mohamed Sadiq for providing necessary facilities in college premises for this research work.

References

- [1] S. Rajeshkumar, B. Tamilarasan and V. Sivakumar (2015). Phytochemical screening and hepatoprotective efficacy of leaves extracts of annona squamosa against paracetamol induced liver toxicity in rats. *Int. J. Pharmacognosy*, **2**: 178-185.



- [2] K. Dinesh, V. Sivakumar, B. Selvapriya, E. Deepika and A. M. Sadiq (2014). Evaluation of hepatoprotective polyherbal formulations contains some Indian medicinal plants. *J. Pharmacognosy and Phytochemistry*, **3**: 1-5.
- [3] D. Arora, M. Kumar and S. D. Dubey (2002). *Centella asiatica* – A review of its medicinal uses and pharmacological effects. *J. Natural Remedies*, **2**: 143-149.
- [4] Kashmira Gohil J, Jagruti Patel A and Anuradha Gajjar K. (2010). Pharmacological Review on *Centella asiatica*: A potential Herbal Cure all. *Indian J. Pharm. Sci.*, **72**: 546-556.
- [5] C. K. Kokate (2001). *Practical Pharmacognosy*, 2001. Vallabh Prakashan, Delhi, 107, 108-111.
- [6] Organization for Economic Co-operation and Development (2001). Guidelines on acute oral Toxicity. (July 2001). <https://ntp.niehs.nih.gov/iccvam/suppdocs/feaddocs/oecd/oecd-gd24.pdf>.
- [7] M. Mujahid, H. H. Siddiqui, A. Hussain and M. S. Hussain (2013). Hepatoprotective effects of *Adenantha pavonina* (Linn.) against anti-tubercular drugs-induced hepatotoxicity in rats. *Pharmacog J.*, **5**: 286-90.
- [8] V. Sivakumar and M. S. Dhanarajan (2010). Antioxidant activity of *Tinospora cordifolia* in Alloxan induced diabetic rats. *Indian J. Pharm. Sci.*, **72**: 795-798.
- [9] D. Das and R. K. Banerjee (1993). Effect of stress on the antioxidant enzymes and gastric ulceration. *Mol Cell Biochem.*, **125**: 115-125.
- [10] H. Aebi (1984). Catalase in vitro. In: *Methods in enzymology* vol. 105. New York: Academic Press. pp.121-16.
- [11] P. Kakkar, B. Das and P. N. Visvanathan (1984). A modified spectrophotometric assay of superoxide dismutase. *Indian J Biochys*; **21**: 130-132.
- [12] S. N. Upadhyay (1997). Therapeutic potential of immunomodulatory agents from plant products. *Immunomodulation*. New Delhi: Narosa Publishing House, **3**: 149-154.
- [13] V. Sivakumar and S. Rajeshkumar (2015). Protective effect of *Andrographis paniculata* on hyperglycemic mediated oxidative damage in renal tissues of diabetic rats. *J. Phytopharmacol.*, **4**: 287-294.
- [14] K. Dinesh, V. Sivakumar, B. Selvapriya, E. Deepika and A. Mohamed Sadiq (2014). Evaluation of hepatoprotective polyherbal formulations contains some Indian medicinal plants. *J. Pharmacog. Phytochemis.* **3**: 1-5.
- [15] M. T. Olaleye, A. C. Akinmoladun, A. A. Ogunboye and A. A. Akindahunsi (2010). Antioxidant activity and hepatoprotective property of leaf extracts of *Boerhaavia diffusa* Linn against acetaminophen-induced liver damage in rats. *Food Chem Toxicol.*, **48**: 2200- 2205.
- [16] S. A. Tasduq, K. Singh, N. K. Satti, D. K. Gupta, K. A. Suri and R. K. Johri (2006). *Terminalia chebula* (fruit) prevents liver toxicity caused by sub-chronic administration of rifampicin, isoniazid and pyrazinamide in combination. *Hum. Exp. Toxicol.*, **25**:111-118.
- [17] V. D. Reddy, P. Padmavathi, S. Gopi, M. Paramahansa and N. Ch.Varadacharyulu (2010). Protective effect of *Emblca officinalis* against alcohol-induced hepatic injury by ameliorating oxidative stress in rats. *Indian J Clin Biochem.*, **25**: 419-424.
- [18] A. I. Mir, B. Kumar, S. A. Tasduq, D. K. Gupta, S. Bhardwaj and R. K. Johri (2007). Reversal of hepatotoxin-induced pre-fibrogenic events by *Emblca officinalis* – a histological study. *Indian J. Exp. Biol.*, **45**: 626-629.
- [19] B. P. Kale, M. A. Kothekar, H. P. Tayade and J. B. Jaju (2003). Effect of aqueous extract of *Azadirachta indica* leaves on hepatotoxicity induced by antitubercular drugs in rats. *Indian J. Pharmacol.*, **35**: 177-180.
- [20] C. P. Sodhi, S. V. Rana, S. K. Mehta, K. Vaiphei, S. Attari and S. Mehta (1997). Study of oxidativestress in isoniazid-rifampicin induced hepatic injury in young rats. *Drug Chem Toxicol.*, **20**: 255-269.
- [21] O. O. Onyema, E. O. Farombi, G. O. Emerole, A. I. Ukoha, G. O. Onyeze (2006). Effect of vitamin E on monosodium glutamate induced hepatotoxicity and oxidative stress in rats. *Indian J. Biochem Biophys.*, **43**: 20-24.
- [22] Sre. P. R. Rathi, T. Sheila, K. Murugesan (2012). Phytochemical screening and In vitro antioxidant activity of methanolic root extract of *Erythrina indica*. *Asian Pac. J. Trop. Biomed.*, S1696e700.